

# The Silicone Pupillary Expansion Ring

This device has proven effective for managing small pupils in eyes with IFIS.

BY JOHN M. GRAETHER, MD

**A** report on the effects of Flomax (tamsulosin; Boehringer-Ingelheim Pharmaceuticals, Inc., Ridgefield, CT) on the iris dilator muscle by Chang and Campbell fueled ophthalmologists' interest in the management of the small pupil, especially in IFIS.<sup>1</sup> Even though I have used several of the mechanical devices for pupillary enlargement, my experience has been primarily with the Graether Pupil Expander (Eagle Vision, Memphis TN) of my own invention.<sup>2</sup> Although it was introduced more than 10 years ago, recent modifications of the device's insertion method have improved the time and ease of insertion and greatly expanded its use.<sup>3,4</sup> The Graether Pupil Expander has proven to be especially effective in cases of IFIS, particularly when the pupil is small initially. This article discusses the use of this silicone pupillary expansion ring for eyes with IFIS as well as the device's limitations.

## PROPERTIES AND ADVANTAGES

The Graether Pupil Expander is an incomplete silicone ring with a groove in its outer surface that engages the sphincter's margin to enlarge the pupil. When expanded, the inside diameter of the ring is 6.3mm. There is a 3.5-mm gap in the ring that is bridged by a thin strap that lies against the iris stroma and gives the phaco tip and other instruments access to the pupil (Figure 1). The Graether Pupil Expander is particularly useful for countering the iris-related abnormalities induced by Flomax.

For one thing, the device's insertion is atraumatic. A smoothly contoured sideport instrument and the silicone ring, in opposition, stretch the sphincter radially. As the ring also expands radially, there are no rotational forces that could tear the iris stroma or root.

The silicone ring's very low mass, soft texture, and broad area of contact avoid pointed pressure on the sphincter, and they add structural support without stress on the tissue.

Excessive stretching of the sphincter does not occur.




Figure 1. The Graether Pupil Expander is placed on the iris sphincter. Adjacent to the incision, note the gap in the ring, which provides access to the pupil.

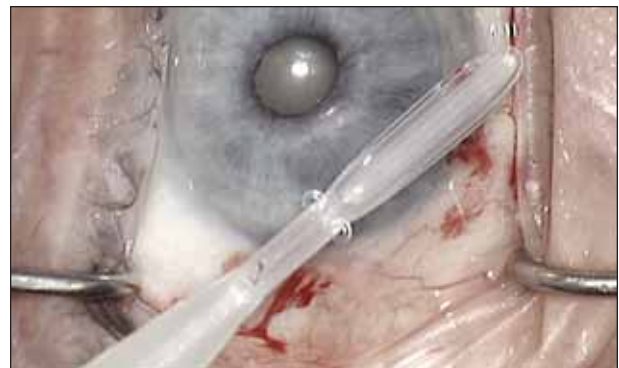


Figure 2. The underside of the pupil expander ring is mounted on the disposable insertion tool. Note the tabs resting against the undersurface of the insertion tool.

The ring gently counteracts the unopposed contractile properties of the sphincter muscle, and the pupil remains circular and has a constant 6.3-mm diameter.

No additional incisions are required, and tenting up of the iris is avoided. The backward curving strap holds the iris away from the primary incision to prevent prolapse, and no part of the device protrudes through the incisions.

In experienced hands, the expander's insertion appears to

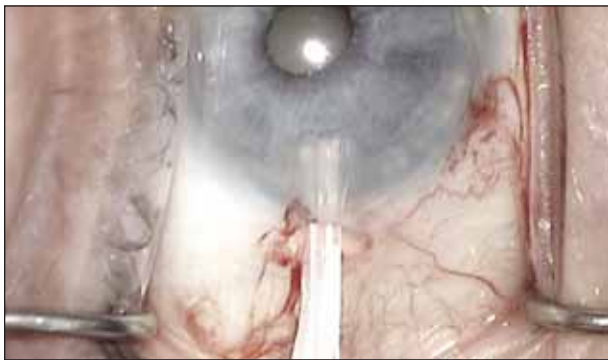


Figure 3. The pupil expander is inserted through the incision with the insertion tool turned on its side so that the edges of the groove form "runners."

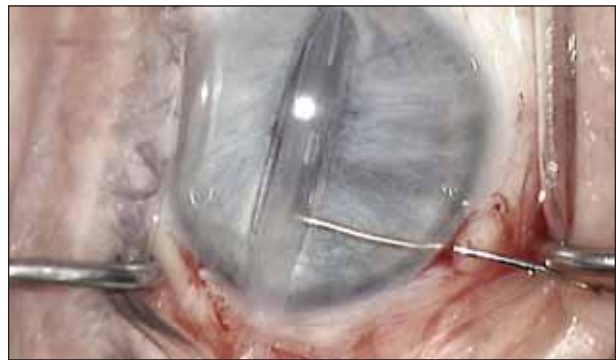


Figure 5. The sideport manipulator's tip is placed in the pupil and moved toward the incision to stretch the sphincter.

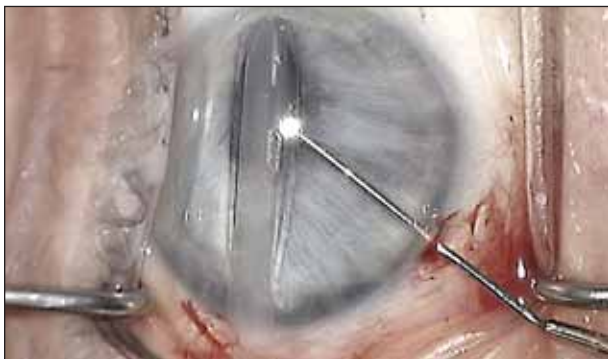


Figure 4. The pupillary margin is engaged with the tip of the pupil expander and pushed to the opposite limbus. The insertion tool is held stationary from this point during the insertion.

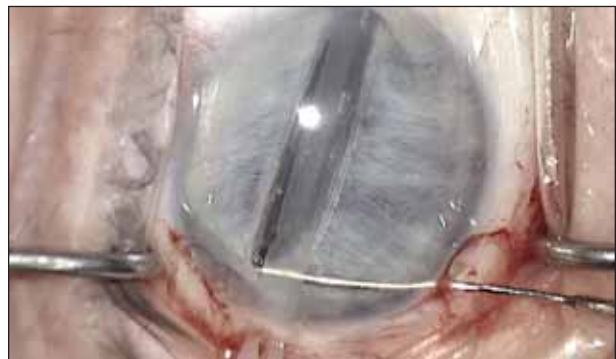

Figure 6. The sphincter's margin is lifted to engage the open end of the expander ring on the distal side away from the sideport incision. Surgeons should lift the sphincter to bring it up into the groove. They should not push down on the insertion tool.

be simple and atraumatic. The surgeon can complete the process in approximately 1 minute and remove the device in a few seconds.

## THE CONTEMPORARY INSERTION TECHNIQUE

The key to consistently and rapidly inserting the device is to positively engage the ring's two open ends by the sphincter's margin prior to releasing the ring from the insertion tool (Figures 2 to 9). The folded tip of the ring engages the sphincter and displaces it toward the limbus opposite the incision. The sideport instrument engages and stretches the proximal side of the sphincter past the open ends of the ring and then rises to engage each side. The entire sphincter is then in the plane of the groove. Releasing the ring will cause it to expand onto and embrace the adjacent sphincter as well as dilate the pupil (Figures 1 and 9). The sideport instrument I prefer is the Graether Sideport Manipulator (AE-2504; ASICO, Westmont, IL). The pupil need only stretch enough to engage the ring, thus avoiding excessive extension or rupture of the sphincter's edge.

If a portion of the ring misses the margin of the sphincter, it can be pushed into the pupil's aperture with the sideport

instrument and allowed to expand onto the iris. My colleague, James Davison, MD, likes to use a cyclodialysis spatula combined with a Lester hook (Katena Products, Inc., Denville, NJ) for this maneuver. Harold Climenhaga, MD, of Edmonton, Canada, employs two Storz Kuglen hooks (Bausch & Lomb, Rochester, NY) and can place the Graether Pupil Expander entirely from the anterior chamber when he misses the sphincter.

## FLOMAX CASES

In my and my colleagues' experience, the pupil in the patient on Flomax usually dilates poorly with pharmacologic agents, but it is not initially extremely miotic. As Chang and Campbell pointed out, because the sphincter muscle is unopposed due to the atrophy of the dilator muscle, the pupil will immediately begin to constrict with any surgical manipulation.<sup>1</sup> The Graether Pupil Expander is easy to insert and functions very well in these cases. When the pupil dilates well initially to 6.5mm or larger, however, the silicone ring expander becomes more difficult to place due to a lack of tension in the sphincter (the resistance in a smaller pupil causes the iris to enter the groove in the ring more readily).

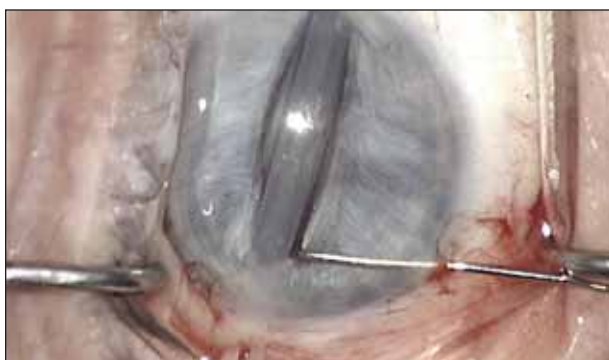

Figure 7. The open end of the ring on the proximal side is engaged to bring the entire pupillary margin into the plane of the groove with the iris' surface up against both tabs.

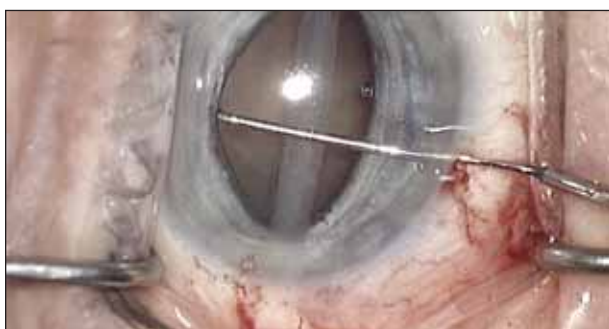

Figure 8. The pupil expander is released from the insertion tool and guided onto the sphincter with the tip of the sideport manipulator.

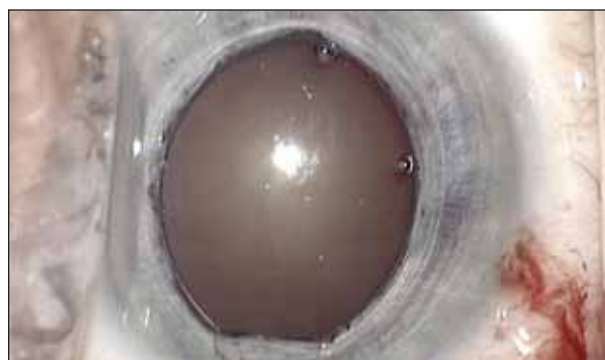

Figure 9. The insertion tool is removed, and Viscoat is added if necessary. Note the strap between the open ends of the ring that is pushed back against the iris at the incision.

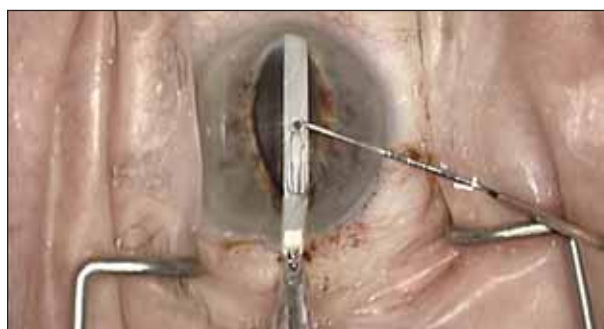

Figure 10. The author uses a reusable insertion tool (under development) for loading and inserting the Graether Pupil Expander.

In patients with IFIS whose pupils initially dilate well (6.5mm or more), the approaches described in the other articles in this series may be preferable.

Whenever a surgeon employs the Graether Pupil Expander to manage a small pupil, I recommend using Viscoat (Alcon Laboratories, Inc., Fort Worth, TX), Discovisc (Alcon Laboratories, Inc.), or another dispersive viscoelastic. Additionally, in cases of IFIS, I may apply extra viscoelastic to the peripheral iris as needed to control the floppy stroma. The placement of the pupil expander ring is more difficult after the capsulotomy, and I do not recommend the maneuver.

It is important that surgeons be aware of a patient's use of Flomax prior to starting cataract surgery.<sup>1,5</sup> My colleagues and I note the drug's use prominently on the preoperative record (medical history) that accompanies the patient into the OR. The surgeon can then select an approach that will minimize the risk of complications associated with iris prolapse and a miotic pupil. Placing the silicone pupil expander using a dispersive viscoelastic such as Viscoat to fill the anterior chamber, the viscoelastic will usually remain in the chamber peripheral to the ring and will dampen the movement of the floppy iris. Occasionally, extra Viscoat may be needed, but it is essential not to get the viscoelastic behind the iris or to overfill the chamber.

## FUTURE DEVELOPMENTS

Eagle Vision, Inc., is developing an optional, reusable insertion instrument intended to reduce the unit cost of the Graether Pupil Expander (Figure 10). With that option, the disposable expander ring will be delivered in a sterile loading tray and easily loaded in the OR. I believe that this alternative method of delivery will become the most efficient and economical means by which to mechanically expand the small pupil. ■

*John M. Graether, MD, is the senior ophthalmic surgeon at The Wolfe Eye Clinic in Marshalltown, Iowa. He has been granted US patent rights to the pupil expander and has a financial interest in this device and the Graether Sideport Manipulator. Dr. Graether may be reached at (641) 754-6200; [jgraether@wolfeclinic.com](mailto:jgraether@wolfeclinic.com).*



1. Chang DF, Campbell JR. Intraoperative floppy iris syndrome associated with tamsulosin (Flomax). *J Cataract Refract Surg.* 2005;31:664-673.
2. Graether JM, inventor; Eagle Vision, Inc., assignee. Pupil Expander and method of using the same. US Patent No. 5 267 553. December 7, 1993.
3. Graether JM. The Graether pupil expander for managing the small pupil during surgery. *J Cataract Refract Surg.* 1996;22:530-535.
4. Graether JM. The silicone ring pupil expander revisited: a new and rapid insertion technique. Video presented at: The AAO Annual meeting; October 14, 2005; Chicago, IL.
5. Chang D. Anticipation is key to managing intraoperative floppy iris syndrome. *Ophthalmology Times.* June 15, 2006;31:12:32.

**Cataract & Refractive Surgery**  
**TODAY**



8500 Wolf Lake Dr., Ste. 110 • P.O. Box 34877  
Memphis, TN 38184 U.S.A.  
1.901.380.7000 • Fax 1.901.380.7001  
1.800.222.7584 • [www.eaglevis.com](http://www.eaglevis.com)